



The Brazilian Journal of INFECTIOUS DISEASES

www.elsevier.com/locate/bjid



Clinical image

Membranous glomerulonephritis secondary to syphilis



Stanley de Almeida Araújo^{a,b,*}, Luiz Flávio Giordano^c, Ariel Augusto de Britto Rosa^c,
Paula Alves Santos do Carmo^b, Kinulpe Honorato-Sampaio^{d,**}

^a Escola de Medicina da Universidade Federal de Ouro Preto, Ouro Preto, MG, Brazil

^b Centro Especializado em Anatomia Patológica, Belo Horizonte, MG, Brazil

^c Hospital Universitário São José, Belo Horizonte, MG, Brazil

^d Centro de Microscopia da Universidade Federal de Minas Gerais, Belo Horizonte, MG, Brazil

ARTICLE INFO

Article history:

Received 25 March 2015

Accepted 29 March 2015

Available online 18 May 2015

A 57-year-old man presented with bilateral leg swelling, myalgia, weight gain, and reduced urine output for three months. He exhibited no signs and symptoms of urinary tract infection or sexually transmitted disease (STD). He reported a past medical history of diabetes mellitus and hypertension for 20 years, and bariatric surgery and abdominoplasty from about five years ago. Blood cell count was normal. Serum creatinine and creatinine clearance were 1.9 mg/dL and 49 mL/min, respectively. A 24-h urine collection revealed 19 g of protein. These results were consistent with nephrotic syndrome. Serological tests for hepatitis and HIV were negative and the venereal disease research laboratory (VDRL) test was positive with a titer of 1:1024. The ultrasound showed normal kidney size with some suggestive features of acute parenchymal disease. He was treated with losartan, furosemide,

hydrochlorothiazide, spironolactone, atorvastatin, heparin, and insulin, which resulted in a reduction of edema. Family members reported sudden personality changes and aggressiveness, pointing to a diagnostic of neurological syphilis disease. Computed tomography showed no abnormalities. VDRL and fluorescent treponemal antibody-absorption test were positive in cerebrospinal fluid, confirming neurosyphilis. A high-dose of intravenous crystalline penicillin was administered for two weeks. After 20 days, proteinuria was 17 g and creatinine was 1.4 mg/dL. A renal biopsy was performed. Light microscopy showed the glomeruli with a thick Bowman's capsule and interstitial fibrosis (Fig. 1A). The immunofluorescence was positive to IgG, C3 and lambda in glomerular basement membrane (Fig. 1B–D). Electron microscopy showed extensive diffuse foot process effacement, and subepithelial

* Corresponding author at: Escola de Medicina da Universidade Federal de Ouro Preto, Campus Morro do Cruzeiro, Ouro Preto, MG, CEP 35400-000, Brazil.

** Corresponding author at: Centro de Microscopia da Universidade Federal de Minas Gerais, Av. Antônio Carlos, 6627, Belo Horizonte, MG 31270-901, Brazil.

E-mail addresses: stanleyaa@gmail.com (S. de Almeida Araújo), kinulpe@yahoo.com.br (K. Honorato-Sampaio).

<http://dx.doi.org/10.1016/j.bjid.2015.03.003>

1413-8670/© 2015 Elsevier Editora Ltda. All rights reserved.

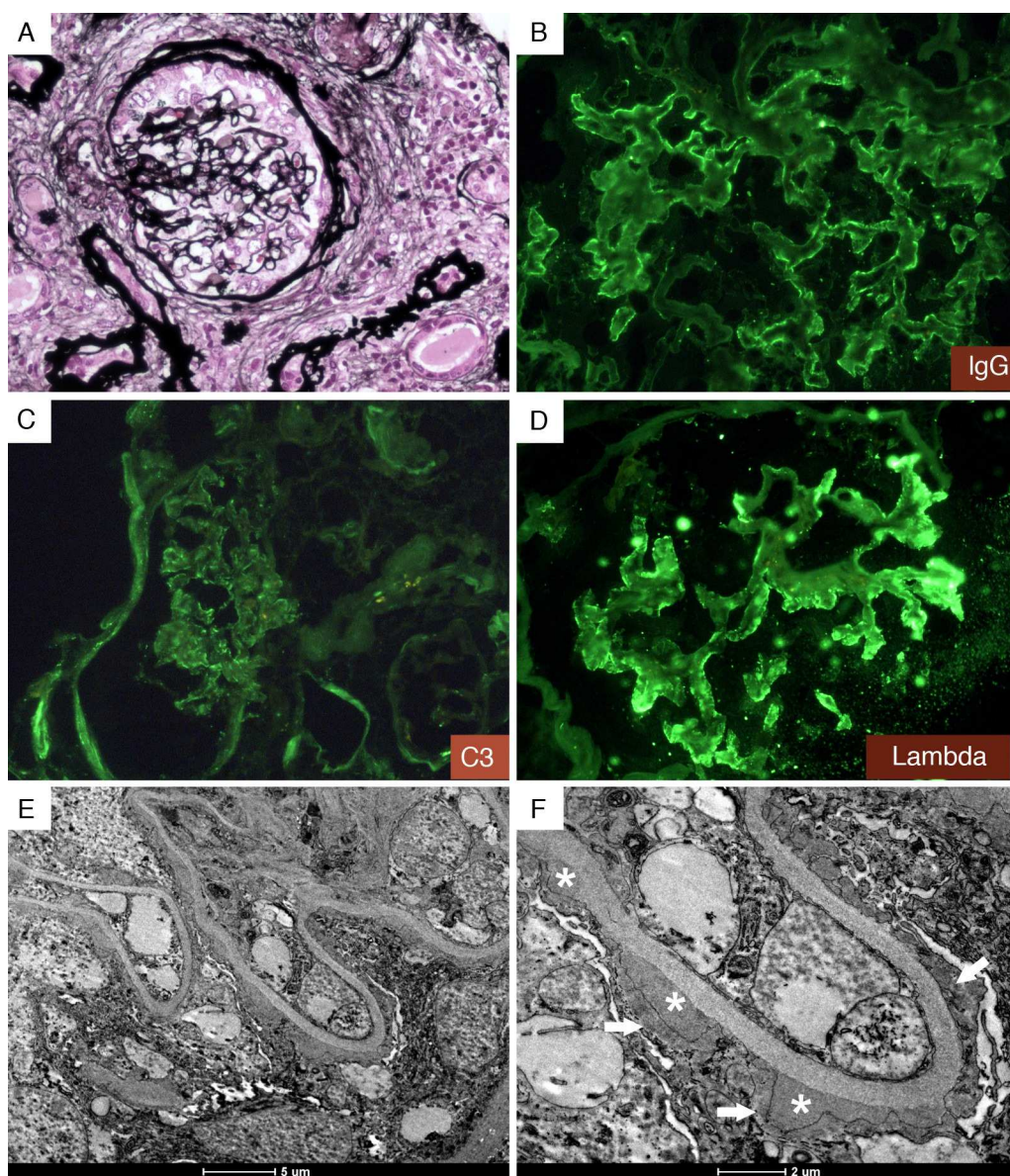


Fig. 1 – Membranous glomerulonephritis secondary to syphilis. (A) Glomerulus with a thick Bowman's capsule and interstitial fibrosis by Jones' Methenamine Silver Stain. Immunofluorescence showing positive staining in glomerular basal membrane for IgG (B), C3 (C) and lambda (D); (E) and (F). Transmission electron microscopy showing extensive diffuse foot process (arrow) and subepithelial electron dense deposits (asterisk).

electron dense deposits (Fig. 1E and F). These results were diagnostic of membranous glomerulonephritis (MGN) secondary to syphilis. Three months after antibiotic treatment, renal function improved and a 24-h urine collection showed 1 g of protein. Syphilis is a cause of MGN, which is not difficult to diagnose in a patient with a known history of this STD.¹ However, syphilis may not be considered as the underlying cause of MGN in an undiagnosed patient,² because of the rarity of this infection in a tertiary stage. If any feature is not compatible with idiopathic MGN or other common causes such as lupus, hepatitis B, nonsteroidal anti-inflammatory drugs, or malignancy, one should investigate uncommon causes of MGN as both treatment and outcome may change.

Conflicts of interest

The authors declare no conflicts of interest.

REFERENCES

1. Krane NK, Espenan P, Walker PD, Bergman SM, Wallin JD. Renal disease and syphilis: a report of nephritic syndrome with minimal change disease. *Am J Kidney Dis.* 1987;9:176-9.
2. Satoskar AA, Kovach P, O'Reilly K, Nadasdy T. An uncommon cause of membranous glomerulonephritis. *Am J Kidney Dis.* 2010;55:386-90.