




Clinical Image

Tapeworm (*Diphyllobothrium nihonkaiense*) detected by abdominal ultrasonography

Ryota Hase ^{a,b,*}, Haruki Mito^a, Yudai Yano^a, Yasuyuki Morishima^c,
Yuichi Hasegawa^d

^a Japanese Red Cross Narita Hospital, Department of Infectious Diseases, Narita, Chiba, Japan

^b Kameda Medical Center, Department of Infectious Diseases, Kamogawa, Chiba, Japan

^c National Institute of Infectious Diseases, Department of Parasitology, Tokyo, Japan

^d Japanese Red Cross Narita Hospital, Department of Laboratory Medicine, Narita, Chiba, Japan

ARTICLE INFO

Article history:

Received 9 February 2023

Accepted 21 April 2023

Available online 5 May 2023

A 16-year-old girl presented with anal discharge of a white thread-like object. She denied additional symptoms. She had consumed raw salmon three weeks ago. Physical examination revealed no abnormal findings, and blood tests were unremarkable. However, abdominal ultrasound revealed a hyperechoic strand-like structure (Fig. 1). Stool examination revealed the presence of cestode ova. Therefore, she was admitted to our hospital and treated with oral praziquantel. A tapeworm, roughly 2.5 m long, was extracted from her feces (Fig. 2). Restriction fragment length polymorphism analysis with PCR-amplified *cox1* gene fragment was performed,¹ which identified the causative cestode was *Diphyllobothrium nihonkaiense*.

In Japan, *D. nihonkaiense* is the most common diphyllobothriasis-causing tapeworm.² The diagnosis was based on the appearance after deworming, and the species was correctly identified using a molecular technique. The effectiveness of ultrasound has been reported in several publications.^{3,4} In cases such ours, ultrasound is useful for

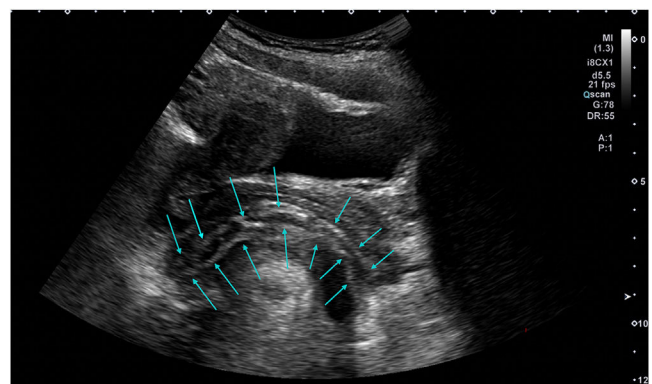


Fig. 1 – Longitudinal view of the rectum showing high echoic strand-like lesion (blue arrows). (For interpretation of the references to color in this figure legend, the reader is referred to the web version of this article.)

* Corresponding author.

E-mail address: hase.ryota@kameda.jp (R. Hase).

<https://doi.org/10.1016/j.bjid.2023.102773>

1413-8670/© 2023 Sociedade Brasileira de Infectologia. Published by Elsevier España, S.L.U. This is an open access article under the CC BY-NC-ND license (<http://creativecommons.org/licenses/by-nc-nd/4.0/>)

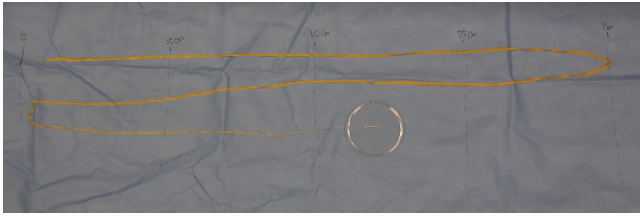


Fig. 2 – The tapeworm unfolded after deworming with praziquantel.

deciding whether to treat patients with praziquantel because the tapeworms are extracted naturally. In conclusion, abdominal ultrasonography can be useful for diagnosing diphyllbothriasis.

Conflicts of interest

The authors declare no conflicts of interest.

Ethical approval

Written informed consent was obtained from the patient's parents.

Authors' contributions

R.H. drafted the manuscript and prepared Fig. 2. Y.M. performed the molecular test for identification and supervised its description. Y.H. prepared Fig. 1. All authors reviewed the manuscript.

Funding

None.

REFERENCES

1. Yamasaki H, Tsubokawa D, Mercado R, Kuramochi T. A simple method for identifying the diphyllbothriids based on mitochondrial DNA analysis. In: Takamiya S, ed. *Materials and Methods in Parasitology*, Nagoya City (Japan): Sankeisha; 2014:47–9.
2. Ikuno H, Akao S, Yamasaki H. Epidemiology of *Diphyllbothrium nihonkaiense* diphyllbothriasis, Japan, 2001–2016. *Emerg Infect Dis.* 2018;24:1428–34.
3. Hiroshima M, Nakagawa M, Ito Y, Shiba A, Ozawa Y, Shibamoto Y. Ultrasonographic findings of *Diphyllbothrium nihonkaiense*: a case report. *Radiol Case Rep.* 2018;14:63–5.
4. Kitamoto H, Inoue S, Okamoto K, Inokuma T. Scanning early catches the worm: abdominal ultrasound as a possible screening method for intestinal cestodes. *Lancet.* 2019;394:1264.