



The Brazilian Journal of INFECTIOUS DISEASES

www.elsevier.com/locate/bjid



Case report

COVID-19 pneumonia in an HIV-positive woman on antiretroviral therapy and undetectable viral load in Porto Alegre, Brazil



Murillo Machado Cipolat^a, Eduardo Sprinz^b  ^{a,b,*}

^a Hospital de Clínicas de Porto Alegre, Infectious Diseases Service, Porto Alegre, RS, Brazil

^b Universidade Federal de Rio Grande do Sul, Faculdade de Medicina, Porto Alegre, RS, Brazil

ARTICLE INFO

Article history:

Received 6 June 2020

Accepted 24 July 2020

Available online 26 August 2020

Keywords:

SARS-CoV-2

COVID-19

HIV

AIDS

ABSTRACT

COVID-19 pandemic has been a problem worldwide. It is important to identify people at risk of progressing to severe complications and to investigate if some existing antivirals could have any action against SARS-CoV-2. In this context, HIV-infected individuals and antiretroviral drugs might be included, respectively. Herein we present the case of a 63-year-old HIV-infected woman with undetectable viral load, on dolutegravir, tenofovir and lamivudine, who was hospitalized due to COVID-19 pneumonia. In spite of having some clinical markers of severity on admission, the patient improved and was discharged after a week. To our knowledge, this is the first report of severe SARS-CoV-2 infection in an HIV-infected individual in Brazil.

© 2020 Sociedade Brasileira de Infectologia. Published by Elsevier España, S.L.U. This is an open access article under the CC BY-NC-ND license (<http://creativecommons.org/licenses/by-nc-nd/4.0/>).

Introduction

COVID-19, caused by the severe acute respiratory syndrome coronavirus type-2 (SARS-CoV-2), has been declared a pandemic in March 2020, following the first case reported in Wuhan, China in December 2019. Some patients, such as those suffering from cardiovascular disease, diabetes mellitus and obesity, were soon identified at greater risk for worse clinical outcomes. Nevertheless, there is still a lot to be discovered regarding this disease. In this context, not only the risk of COVID-19 complications among people living with HIV (PLWH)

remains uncertain, but also the potential protective benefits of antiretroviral (ARV) drugs.

Despite of more than 12 million cases of COVID-19 worldwide as early July, reports of HIV/Sars-CoV-2 co-infection are still uncommon,¹ with the first known case in the USA only being reported on May 22, 2020.² People living with HIV accounted for only 1% of 16,749 patients with COVID-19 hospitalized in the United Kingdom, on a large prospective observational cohort study, with HIV having no impact on survival.³ Thereafter, the prognosis of PLWH after the diagnosis of COVID-19 has also been a subject of debate.⁴ While some researchers believe that HIV immunosuppression could result in greater susceptibility to SARS-CoV-2 infection,⁵ others believe that these patients would be at a lower risk of complications, since impairment in cellular immunity might be associated with less inflammation,⁶ reducing the incidence

* Corresponding author.

E-mail address: esprinz@hcpa.edu.br (E. Sprinz).

<https://doi.org/10.1016/j.bjid.2020.07.009>

1413-8670/© 2020 Sociedade Brasileira de Infectologia. Published by Elsevier España, S.L.U. This is an open access article under the CC BY-NC-ND license (<http://creativecommons.org/licenses/by-nc-nd/4.0/>).

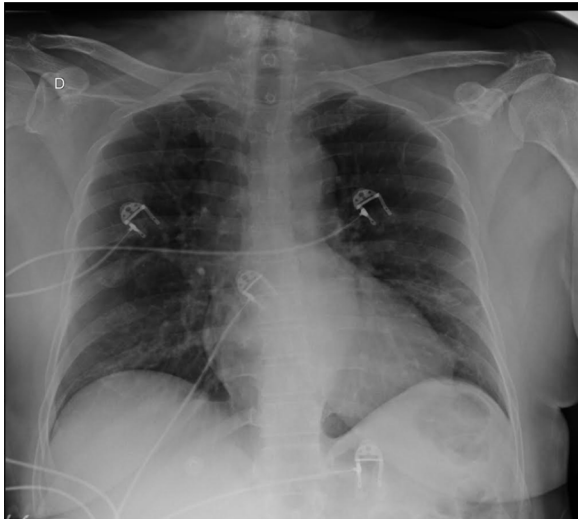


Fig. 1 – Chest X-ray with peripheral opacities in inferior lobes of both lungs.

of cytokine storm which has been associated with more severe cases of COVID-19.

There is also some controversy about the potential advantages against SARS-CoV-2 from being on ARVs.⁷ There is some *in vitro* evidence that these drugs could have an impact against this virus.^{8,9} Herein we present the case of an HIV-infected woman on antiretroviral therapy who was hospitalized at our center with COVID-19 pneumonia.

Case report

A 63-year-old woman was admitted to COVID-19 Unit at Hospital de Clinicas de Porto Alegre (HCPA), on southern Brazil, on May, 2020. The patient had been diagnosed with HIV infection in 2005, and was on tenofovir (TDF), lamivudine (3TC), and dolutegravir (DTG) since November 2019 (before she was on atazanavir/ritonavir, switched for DTG). Her viral load had been undetectable for a long time and her CD4+ cell count was 426 cells/mm³ (CD4/CD8 ratio 1.25). Systemic arterial hypertension (SAH), well controlled with hydrochlorothiazide and losartan, was the other comorbidity she had.

At presentation, she complained of fever (39°C), myalgia, inappetence, nausea, abdominal pain, diarrhea, hyposmia and hypogeusia, in addition to cough and dyspnea for a week. Upon admission, white blood cells (WBC) count was 9250 cells/mm³ (76% neutrophils, and 16% lymphocytes). She had elevated C-reactive protein (65.5 mg/L), total creatine kinase (307 U/L) and lactate dehydrogenase (316 U/L). Serum creatinine was 0.84 mg/dL and she had no abnormalities in clotting tests, including a D-Dimer level of 0.42 ug/mL (with our reference value being up to 0.5 ug/mL). First arterial blood gas analysis (ABG) was performed with the patient on supplemental oxygen through a nasal cannula, but she did not present hypoxemia, with a 107 mmHg pO₂ and a peripheral oxygen saturation (SpO₂) of 98.5%. Chest X-ray exhibit opacities in middle thirds of both lungs (Fig. 1). Sars-CoV-2 was detected by RT-PCR in nasopharyngeal secretion swab.

The patient was treated with supportive measures that included oxygen via nasal cannula and received antibiotic therapy with amoxicillin/clavulanate for a total of seven days. After giving consent, she was randomized to one of the arms of a randomized clinical trial (Coalition-1 trial¹⁰) and received hydroxychloroquine 400 mg bid plus azithromycin 500 mg per oral according to trial protocol, with no side effects related to any of these therapies during this period. Even though she presented some severity markers on admission, she had a favorable clinical evolution, with no need for treatment in ICU or requiring more invasive forms of oxygen therapy, being discharged in good clinical conditions seven days after hospitalization.

Conclusion

To our knowledge, this is the first reported case of COVID-19 disease in an HIV-infected individual in Brazil and remains the only one that we had the opportunity to care. This finding is of special interest, as Porto Alegre, the capital of the southernmost state of Brazil (Rio Grande do Sul), is one of the cities with highest HIV incidence in Brazil.¹¹ This report has the purpose to illustrate the several peculiarities of SARS-CoV-2 infection worldwide. Although the patient presented a severe course of COVID-19, the ARVs she was taking did not protect her from acquiring the infection.

Among the drugs used to treat HIV, lopinavir/ritonavir was the first to assessed against SARS-CoV-2. In spite of the studies in 2003 during SARS epidemic showing a decrease in mortality, intubation rates and unfavorable outcomes on SARS with the use of lopinavir/ritonavir,¹² a recent clinical trial showed no benefit of this medication for the treatment of severe cases of COVID-19.¹³ Other combinations of protease inhibitors are under testing, with atazanavir/ritonavir showing greatest inhibitory potential *in vitro* against SARS-CoV-2.⁸ A clinical trial of darunavir/cobicistat for treatment of COVID-19 is currently on progress in China.¹⁴ Other ARVs have also shown some activity *in vitro* and in animal models. DTG, an integrase inhibitor, had demonstrated activity against SARS-CoV-2.^{8,9,15,16} Likewise, TDF, a nucleotide analogue reverse transcriptase inhibitor widely used in the treatment of HIV and Hepatitis B infections, has emerged as a new investigative agent against COVID-19. It is from the same class as remdesivir, a novel nucleotide analogue that has activity against SARS-CoV-2 *in vitro*¹⁷ and has been recommended for hospitalized patients with severe COVID-19 in many guidelines.¹⁸ However, no ARV has demonstrated clinical impact so far.

One of the first published case series, comprising of 33 patients hospitalized for COVID-19 followed up at HIV centers in Germany, suggested that although SARS-CoV-2 infection could occur during treatment with ARVs, these patients did not appear to be at risk for worse clinical outcomes among those with symptomatic COVID-19.¹⁹ A recent large Spanish cohort study of 77,590 HIV-infected people on ARVs identified similar risk factors for hospitalization, admission to ICU, and death when compared to the general population.²⁰ However, HIV-infected patients on TDF/FTC had a lower risk of COVID-19 and related hospitalization than those receiving other therapies. Whether the difference observed is due to the

profile features of patients using this ART or the direct antiviral effect of the drug is still a matter of debate.²⁰ Currently, one trial combining tenofovir-alarafenamide/emtricitabine and lopinavir/ritonavir to treat COVID-19 patients and another with tenofovir/emtricitabine as pre-exposure prophylaxis against COVID-19 in health care workers are on progress.²¹ In our patient, these ARVs did not prevent SARS-CoV-2 infection. Still, a lot is still to come regarding this coronavirus infection and the clinical course in HIV-infected individuals and the possible impact of ARVs.

REFERENCES

- Blanco JL, Ambrosioni J, Garcia F, et al. COVID-19 in patients with HIV: clinical case series. *Lancet HIV*. 2020;7:e314-6, [http://dx.doi.org/10.1016/S2352-3018\(20\)30111-9](http://dx.doi.org/10.1016/S2352-3018(20)30111-9).
- Patel RH, Pella PM. COVID-19 in a patient with HIV infection. *J Med Virol*. 2020, <http://dx.doi.org/10.1002/jmv.26049>. Online ahead of print. May 22; 10.1002/jmv.26049.
- Docherty AB, Harrison EM, Green CA, et al. Features of 16,749 hospitalized UK patients with COVID-19 using the ISARIC WHO clinical characterization protocol. *BMJ*. 2020, <http://dx.doi.org/10.1136/bmj.m1985>. May 22;369:m1985.
- Ridgway JP, Farley B, Benoit JL, et al. A Case Series of Five People Living with HIV Hospitalized with COVID-19 in Chicago, Illinois. *AIDS Patient Care and STDs*. 2020;34(8):331-5, <http://dx.doi.org/10.1089/apc.2020.0103>. Epub 2020 May 29.
- World Health Organization. Q&A on COVID-19, HIV and antiretrovirals; 2020. Available at: www.who.int/news-room/q-a-detail/q-a-on-covid-19-hiv-and-antiretrovirals. [Accessed 9 July 2020].
- Mascolo S, Romanelli A, Carleo MA, Esposito V. Could HIV infection alter the clinical course of SARS-CoV-2 infection? When less is better. *J Med Virol*. 2020, <http://dx.doi.org/10.1002/jmv.25881>.
- Ballester-Arnal R, Gil-Llario MD. The Virus that Changed Spain: Impact of COVID-19 on People with HIV. *AIDS Behav*. 2020;24(8):2253-7, <http://dx.doi.org/10.1007/s10461-020-02877-3>.
- Beck BR, Shin B, Choi Y, Park S, Kang K. Predicting commercially available antiviral drugs that may act on the novel coronavirus (SARS-CoV-2) through a drug-target interaction deep learning model. *Comput Struct Biotechnol J*. 2020;18:784-90, <http://dx.doi.org/10.1016/j.csbj.2020.03.025>, eCollection 2020.
- Khan RJ, Jha RK, Amera GM, et al. Targeting SARS-CoV-2: a systematic drug repurposing approach to identify promising inhibitors against 3C-like proteinase and 2'-O-ribose methyltransferase. *J Biomol Struct Dyn*. 2020:1-14, <http://dx.doi.org/10.1080/07391102.2020.1753577>. Published online 2020 Apr 20.
- <https://clinicaltrials.gov/ct2/show/NCT04322123?term=coalition&cond=Covid19&cntry=BR&draw=2&rank=3>.
- Boletim Epidemiológico HIV/Aids 2019, Departamento de Doenças de Condições Crônicas e Infecções Sexualmente Transmissíveis, da Secretaria de Vigilância em Saúde, do Ministério da Saúde (DCCI/SVS/MS): www.aids.gov.br/pt-br/pub/2019/boletim-epidemiologico-de-hiv-aids-2019.
- Chan KS, Lai ST, Chu CM, et al. Treatment of severe acute respiratory syndrome with lopinavir/ritonavir: a multicentre retrospective matched cohort study. *Hong Kong Med J*. 2003;9:399-406.
- Cao B, Wang Y, Wen D, et al. A Trial of Lopinavir-Ritonavir in Adults Hospitalized with Severe Covid-19. *N Engl J Med*. 2020;382(19):1787-99, <http://dx.doi.org/10.1056/NEJMoa2001282>. Epub 2020 Mar 18.
- <https://clinicaltrials.gov/ct2/show/NCT04252274>.
- Elfiky AA. Ribavirin, Remdesivir, Sofosbuvir, Galidesivir, and Tenofovir against SARS-CoV-2 RNA dependent RNA polymerase (RdRp): a molecular docking study. *Life Sci*. 2020;253:117592, <http://dx.doi.org/10.1016/j.lfs.2020.117592>.
- Park SJ, Yu KM, Kim YI, et al. Antiviral efficacies of FDA-approved drugs against SARS-CoV-2 infection in ferrets. *mBio*. 2020;11(3):e01114-20, <http://dx.doi.org/10.1128/mBio.01114-20>.
- Clososki GC, Soldi RA, Silva RM, et al. Tenofovir disoproxil fumarate: new chemical developments and encouraging in vitro biological results for SARS-CoV-2. *J Braz Chem Soc*. 2020;00:1-5, <http://dx.doi.org/10.21577/0103-5053.20200106>.
- Beigel JH, Tomashek KM, Dodd LE, et al. Remdesivir for the Treatment of Covid-19 - Preliminary Report. *N Engl J Med*. 2020, <http://dx.doi.org/10.1056/NEJMoa2007764>. Online ahead of print. *NEJMoa2007764*.
- Härter G, Spinner CD, Roeder J, et al. COVID-19 in people living with human immunodeficiency virus: a case series of 33 patients. *Infection*. 2020:1-6, <http://dx.doi.org/10.1007/s15010-020-01438-z>. Online ahead of print.
- Del Amo J, Polo R, Moreno S, Díaz A, et al. Incidence and Severity of COVID-19 in HIV-Positive Persons Receiving Antiretroviral Therapy: A Cohort Study. *Ann Intern Med*. 2020, <http://dx.doi.org/10.7326/M20-3689>. Online ahead of print. M20-3689.
- <https://clinicaltrials.gov/ct2/show/NCT04334928>.